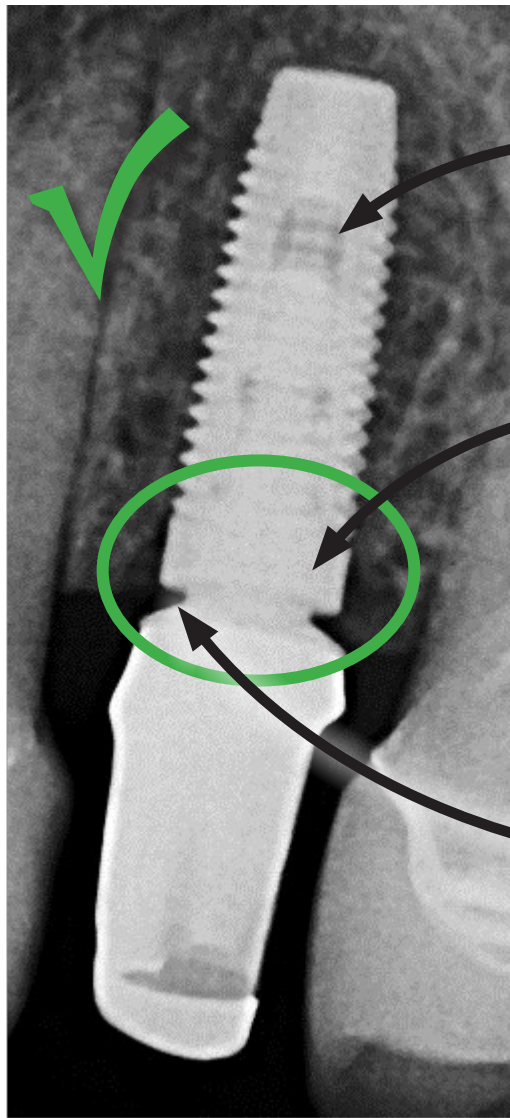


Proper Seating of an Implant One Abutment



Approximately 3 threads are visible, but this is not a good indicator

When fully seated there is no visible gap in the tapered connection area. The implant and abutment appear as one.

When any gap is visible the connection is not properly seated

A gap between the implant and abutment is normal. Ideally soft tissue will fill this space.

